

## Detection of Iron in a Blackish Lesion in a Case of Feline Corneal Sequestration

Hiroyasu EJIMA, Naruo HARA<sup>1)</sup>, and Hiroshi KAJIGAYA<sup>2)</sup>

Departments of Surgery and <sup>1)</sup>Chemistry, School of Veterinary Medicine, Nippon Veterinary and Animal Science University, and <sup>2)</sup>Nippon Advanced School of Medical Technology, 1-7-1 Kyonan-cho, Musashino, Tokyo 180, Japan

(Received 30 October 1992/Accepted 15 July 1993)

**ABSTRACT.** Qualitative and quantitative analyses showed that there was iron (Fe) in a blackish lesion removed from a cat with severe corneal sequestration. Chromatic compound did not extract. The Fe content of the lesion was about 100 times higher than that of a normal cornea, as measured by X-ray fluorescence. Results of other chemical analyses indicated that the Fe in the blackish cornea was not derived from blood in the neovascularized limbus.—**KEY WORDS:** cornea, Fe, sequestration.

*J. Vet. Med. Sci.* 55(6): 1051–1052, 1993

Feline corneal sequestration is a form of corneal degeneration [3–8, 10], and was reported by Verwer [12] in 1965. It has been found in various breeds, including Persian, Himalayan, domestic shorthair, and Siamese [9]. These breeds are predisposed to develop corneal sequestration [4]. This condition has also been described as cornea nigrum, partial mummification, focal degeneration, and black lesion [6]. The cause of corneal sequestration remains unclear.

We have already reported clinical and pathological findings in eight cases of this disease [2]. The presence of an undefined melanin-like pigment was confirmed histopathologically [2]. However, the cause and mechanism of coloration are still unknown [4, 10]. Here we report the results of chemical analyses of the blackish cornea obtained from a cat with severe sequestration.

A two-year-old male Himalayan cat with severe corneal sequestration (Fig. 1) was seen at the Veterinary Medical Teaching Hospital of our University. The examination was done with an ophthalmoscope, a biomicroscope, fluorescein staining, and the Schirmer tear test [2]. Under GOF general anesthesia the blackish lesion was removed by superficial keratectomy [2]. The superficial part of the cornea was removed with a Castroviejo trephine (6 mm diameter) and a corneal dissecting spatula (Beaber 69).

The excised blackish cornea was crushed with a glass bar on a glass slide. Microscopic examination revealed the presence of yellowish-brown fibrous tissue. The results of a hemochrome crystallization test [11] and a luminol test [9] of the fibrous tissue were negative.

The blackish cornea was homogenized in distilled water with a glass homogenizer and a pellet was obtained by centrifugation. The pellet was homogenized in 0.1 M hydrochloric acid, 0.1 M sodium hydroxide, acetone, toluene, ether, and a 2:1 mixture of chloroform and methanol in that order to obtain each extract. Absorption spectrophotometry of each extract was done at wavelengths of from 400 to 600 nm. No significant absorption spectrum was detected in any extract.

Another sample of corneal homogenate was emulsified with acetone. A few drops of a 10% solution of sodium hydroxide were added, and then the emulsion was sonically disrupted for 15 min. The upper part of the emulsion, an aqueous layer, turned into a brownish colloidal fluid.

Since dissolution of the pigment compounds could not

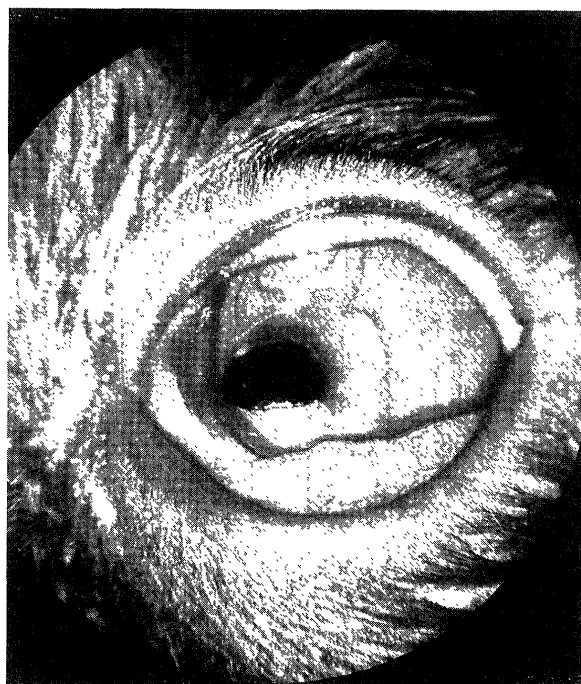


Fig. 1. Severe sequestration of the left cornea. This was a two-year-old male Himalayan cat. There was corneal necrosis, chronic ulcerative keratitis, edema, neovascularization, lacrimation, and conjunctivitis. The photograph was taken with a portable ophthalmoscopic camera (RC-2, Kowa, Japan) and color slide film (ASA100, Fuji, Japan).

be confirmed in this fluid, detection of inorganic ions was attempted by the method of Cotton *et al.* [1]. When 1 N potassium ferrocyanide solution was dropped onto the blackish cornea calcified by the addition of sulfuric acid and hydrogen peroxide, ferrocyanide (Berlin blue) turned a dark blue. When 1 N potassium thiocyanate was added, the ferrothiocyanate changed to a color like that of fresh blood. The result of this qualitative test confirmed the presence of Fe ions. The calcified colloidal fluid also contained Fe ions. These ions were not found in a normal cornea.

Fluorescein X-ray analysis was done to directly confirm the presence of Fe in the blackish cornea. After dehydration with acetone, the cornea was placed between two cover glasses and then vacuum dried. The thin membrane was trimmed into a 2.5 mm-square sample for X-ray fluorescence spectrometry. Elements from potassium to

Table 1. Intensity of X-ray fluorescence of metallic elements in blackish and normal corneas

Element	Cornea	
	Blackish	Normal
Iron	1088	10
Nickel	140	— <sup>b)</sup>
Chromium	N.D. <sup>a)</sup>	—
Manganese	N.D.	—
Copper	N.D.	—
Tin	N.D.	—

a) N.D., Not detected.

b) —, Not tested.

lead were scanned, and the results are shown in Table 1. The count was high for Fe in the blackish cornea. The Fe count in the normal cornea was extremely low.

Quantitative assay of Fe was then done by inductively coupled plasma (ICP) emission spectrometry. The blackish cornea (0.73 mg, dry weight), which had been prepared for X-ray fluorescence spectrometry, was used. With an ICP emission spectrometer, detection of Fe was attempted at 259.94 nm. The content of Fe was 1.07  $\mu\text{g}/\text{mg}$ .

When hemoprotein is treated with alkaline pyridine and reduced with glucose, hemochrome is formed. Luminol in an alkaline solution emits light by catalysis with an Fe complex when an oxidizer is present. If there was blood-derived heme in the blackish cornea, the two reactions should have been positive. In the blackish cornea, however, both reactions were negative. Accordingly, it was suggested that the Fe detected in the blackish cornea was not derived from blood in the neovascularized limbus.

Chromatic compounds were not extracted from the cornea samples into the acid solution, the basic solution, or the organic solvent, so the substance that caused it to appear blackish was probably neither heme nor melanin. The colloidal substance mentioned earlier was dissolved from the acetone-emulsified and minutely crushed blackish cornea with sodium hydroxide solution and by ultrasonic vibration; that is, it was released from the tissue. For this reason, we believe that this brownish colloid contained Fe.

## REFERENCES

1. Cotton, F. A., Darlington, C. L., and Lynch, L.D. 1980. Investigation of the quantitative aspects of equilibrium. pp. 664-668. *In Chemistry-An Investigative Approach*, revised ed., Houghton Mifflin, Boston.
2. Ejima, H., Kajigaya, H., and Hara N. 1992. *Jpn. J. Small Anim. Vet. Assoc.* 32: 3-10.
3. Formston, C., Bedford, P. G. C., Staton, J. F., and Tripathi, R. C. 1974. *J. Small Anim. Pract.* 15: 19-25.
4. Gelatt, K. N. 1991. Feline ophthalmology. pp. 542-544. *In: Veterinary Ophthalmology*, 2nd ed., Lea & Febiger, Philadelphia.
5. Knecht, C. D., Schiller, A. G., and Small, E. 1966. *J. Am. Vet. Med. Assoc.* 149: 1192-1193.
6. Lightowler, C. H., Bruhl-Day, R., and Herrera, H. D. 1987. *Feline Pract.* 17: 9-12.
7. Peiffer, R. L. and Gelatt, K. N. 1976. *Feline Pract.* 6: 37-40.
8. Souri, E. 1972. *VM/SAC.* 67: 155-158.
9. Specht, W. 1937. *Dtsch. Z. Gericht. Med.* 28: 225-234.
10. Startup, F. G. 1988. *J. Small Anim. Pract.* 29: 476-486.
11. Tsukamoto, H. and Okui, S. 1960. pp. 222-224. *In: Saiban Kagaku*, Nanzando, Tokyo (in Japanese).
12. Verwer, M. A. 1965. *Scientific Proceedings of the Am. Anim. Hosp. Assoc.* 112-118.